

Prevalence of Haemogregarine Parasites in Three Freshwater Turtle Species in a Population in Northeast Georgia, USA

¹A.K. Davis and ²S.C. Sterrett

¹Odum School of Ecology, The University of Georgia, Athens GA 30602, USA

²Warnell School of Forestry and Natural Resources, The University of Georgia, Athens GA 30602, USA

Corresponding Author: A.K. Davis, Odum School of Ecology, The University of Georgia, Athens GA 30602, USA

ABSTRACT

Intracellular Haemogregarine parasites (Order Eucoccidiorida, suborder Adeleorina) are often found in freshwater turtles, appearing as banana-shaped structures in the cytoplasm of host erythrocytes. They are thought to be transmitted by leeches, although it is not clear if turtles with high leech parasitism also have high prevalence of Haemogregarine infections. We investigated this idea in freshwater turtles from a pond population in Northeastern Georgia, USA. Turtles were captured with baited hoop traps and blood samples obtained to make blood smears. A total of 23 turtles were captured representing 3 species - 2 that are aerial basking (*Trachemys scripta* and *Chrysemys picta*) and one bottom-dwelling species (*Sternotherus odoratus*). The incidence and severity of Haemogregarine infections was recorded from the blood smears. Multiple stages of intraerythrocytic gametocytes were observed, but the exact identity of the parasite was unknown. Initial evidence from DNA extraction and gene sequencing indicated the parasite was a member of the Hepatozoon clade of the suborder Adeleorina. Of all turtles, 52% of turtles were infected, which was within the range reported for other populations in North America (45-100%). The turtle species with the highest prevalence (*S. odoratus*, 88.9%) was also the one known to harbor the most leeches. Moreover, female turtles were more likely to be infected than males (87.5 vs. 50.0%), which is also consistent with sex-related patterns of leech parasitism. Despite the generally high incidence of infection in this population, most infections were mild, as less than 1% of erythrocytes harbored Haemogregarines on average, which is a pattern found in other populations. Results from this study add to a growing body of literature on the nature of this host-parasite relationship.

Key words: Haemogregarine parasites, freshwater turtles, Northeast Georgia, leeches, *Trachemys scripta*, *Chrysemys picta*, *Sternotherus odoratus*

INTRODUCTION

Freshwater turtles are hosts to a wide variety of pathogens and parasites (Segade *et al.*, 2006; McAllister *et al.*, 2008; Zelmer and Platt, 2008), including intraerythrocytic blood parasites in the Haemogregarine group (Order Eucoccidiorida, suborder Adeleorina). In fact, Haemogregarine parasites are the most widely-distributed blood parasites of turtles world-wide (Telford, 2009). These parasites are typically characterized by sausage-shaped intracytoplasmic gametocytes within host erythrocytes and are not necessarily host-specific (Campbell and Ellis, 2007). Within North American freshwater turtles, Haemogregarine infections have been investigated in a number of turtle populations, including sites in Texas (Wang and Hopkins, 1965), Illinois (Marquard, 1966),

Kentucky (Strohlein and Christensen, 1984), Nebraska (McAuliffe, 1977), Louisiana (Acholonu, 1974), Tennessee (Edney, 1949) and Ontario, Canada (Siddall and Desser, 1992). In most cases, observed infection levels were low, with less than 1-2% of red blood cells affected and most affected turtles in these studies were reported as otherwise healthy, although there are reports of heavy infections causing poor health in some turtle populations (Knotkova *et al.*, 2005).

Haemogregarine parasites are thought to be transmitted to turtles by leeches (Paperna, 1989; Siddall and Desser, 2001) and in general, larger turtles are more prone to leech attachment because of their larger surface area (Readel *et al.*, 2008). However, turtles that inhabit the bottom of ponds tend to harbor more leeches than do basking turtles, regardless of body size (Readel *et al.*, 2008). Ryan and Lambert (2005) confirmed this experimentally by showing preferential attachment by leeches to a bottom-dwelling species, *Sternotherus odoratus*, over an aerial-basking species, *Graptemys geographica*. This species-preference by leeches should therefore lead to differences in Haemogregarine prevalence among species, with bottom-dwelling species having highest prevalence. One field study showed support for this idea; within 4 freshwater turtle species examined from a pond in Kentucky, the highest prevalence of Haemogregarine parasites was in the bottom-dwelling *S. odoratus* (Strohlein and Christensen, 1984). In addition, there is evidence that female aquatic turtles are more prone to leech parasitism than males (McCoy *et al.*, 2007), likely because of their larger body size and greater surface area for leech attachment. However, it is not known if this also translates to higher Haemogregarine parasitism in female turtles.

Recently, we had the opportunity to examine a collection of turtle specimens from a pond in Northeast Georgia for Haemogregarine blood parasites. The turtle species included two aerial basking species, yellow-bellied slider (*Trachemys scripta*) and painted turtle (*Chrysemys picta*) and the bottom-dwelling common musk turtle (*S. odoratus*). Given that musk turtles are known to harbor more leeches than the other two species, we expected to find the highest Haemogregarine infection prevalence in this species. Here we describe the results of this investigation, along with a summary of Haemogregarine prevalence in other freshwater turtle populations across North America, which we compiled from published records.

MATERIALS AND METHODS

Capturing and processing turtles: We captured wild turtles between August 27-30, 2007 in a permanent pond located in Whitehall Forest, a 300 hectare tract of land which acts as an extension of the Daniel B. Warnell School of Forestry and Natural Resources at the University of Georgia, which is located in Athens, GA, USA. Three species of aquatic turtles (*C. picta*, *Sternotherus odoratus* and *Trachemys scripta* are shown in Fig. 1a-c) were trapped using baited hoop traps (Legler, 1960). Captured turtles were transported to the lab where we recorded the Carapace Length (CL) of each individual using calipers, recorded the sex based on external characters, then obtained a blood sample. For the sampling, a small amount of blood (<1cc) was taken from the subcarapacial venipuncture site with a 27-gauge needle following Hernandez-Divers *et al.* (2002). Immediately following blood sampling, standard blood films were made using a clean slide and a small drop of blood. Slides were then air-dried and stained with Giemsa. All turtles were released at their site of capture later the same day.

Examining blood films: Each slide was viewed under 1000X (oil) with a standard light microscope and was moved in a zig-zag fashion so that all parts of the smear were eventually viewed. For each turtle 100 fields of view were examined and all stages of Haemogregarine



Fig. 1: Photos of turtle species examined in this study. (a) painted turtle (*Chrysemys picta*), (b) juvenile musk turtle (*Sternotherus odoratus*) and (c) yellow-bellied slider (*Trachemys scripta*). Top and middle photos by A. Grosse. Bottom photo by S. Sterrett

parasites were counted, following descriptions given in Telford (2009). At this magnification, fields of view had an average of 80 (± 13 SD) erythrocytes (Davis, *unpubl. data*), so this was equivalent to examining ~8000 cells per turtle. With this value, the number of cells affected by Haemogregarine gametocytes was transformed into a percentage (of erythrocytes) for comparison with other published reports.

RESULTS

Light microscopy observations: Multiple stages of intraerythrocytic Haemogregarine gametocytes were observed in this study. These included trophozoites, premeronts, meronts, gamonts and in heavily infected hosts, free-living gamonts (Fig. 2). Most appeared light blue with

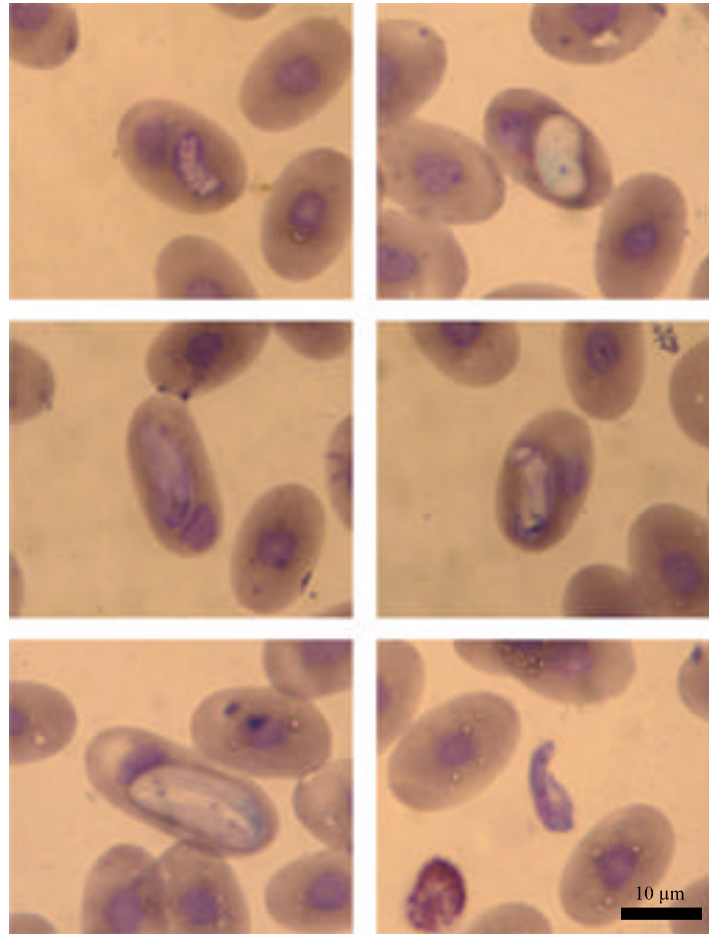


Fig. 2: Photomicrographs of Haemogregarine parasites (various stages, including extra-cellular) observed in turtle blood smears for this study

giemsa staining. In the majority of cases, gametocytes tended to alter erythrocyte shape by extending the cell length and also by displacing the nucleus to one pole of the cell. Based on morphology, the specific identity of these parasites was not known, although preliminary evidence gathered from DNA extraction and gene sequencing of one sample of blood obtained from an infected *S. odoratus* confirmed that the organism was included in the suborder Adeleorina, which also includes the family Haemogregarinidae to which the Haemogregarina belong. More specifically, the organism appeared to belong in the Hepatozoon clade.

Prevalence: A total of 23 turtles were captured and examined for Haemogregarine parasites. Prevalence varied from 22.2% for *C. picta*, 40.0% for *T. scripta* and 88.9% for *S. odoratus* (Table 1). Interestingly, the rank order of these prevalence values corresponds with that from a similar investigation conducted in Kentucky, where the same species were examined (Strohlein and Christensen, 1984), although the overall prevalence was higher in that study. We were able to determine the gender of 18 of the turtles we examined (8 females, 10 males) and these spanned the three species evenly. Overall, 5 males were infected with Haemogregarine parasites (50.0%), while 7 females (87.5%) were.

Table 1: Prevalence of haemogregarine parasites in turtle species examined in this study. For comparison, data is shown from a prior study where the same turtle species were examined

Species	Mean carapace length (mm)	No. of parasitized	Total sampled	Prevalence (%)	Kentucky population*
<i>C. picta</i>	115	2	9	22.2	36.4
<i>T. scripta</i>	123	2	5	40.0	78.6
<i>S. odoratus</i>	80	8	9	88.9	96.3
Grand total		12	23	52.2	78.8

*From Strohlein and Christensen (1984)

Table 2: Levels of haemogregarine parasitemia in turtle species examined in this study. For all turtle blood smears, 100 fields of view were examined at 1000X

Species	n*	Ave. parasitemia (% cells affected)	SD	Min.	Max.
<i>C. picta</i>	2	0.015	0.003	0.013	0.017
<i>T. scripta</i>	2	0.063	0.018	0.050	0.075
<i>S. odoratus</i>	8	0.346	0.347	0.012	1.024
Grand total	12	0.244	0.316	0.012	1.024

*No. of infected turtles

Table 3: Prevalence of haemogregarine parasites in aquatic turtle populations in North America, based on published data

State/Province	n*	Prevalence (%)	Reference
Ontario	366	68.0	Siddall and Desser (1992)
Illinois	31	45.2	Marquard (1966)
Texas	44	75.0	Wang and Hopkins (1965)
Kentucky	71	77.4	Strohlein and Christensen (1984)
Louisiana	95	100.0	Acholonu (1974)
Tennessee	23	72.0	Edney (1949)
Georgia	23	52.2	This study
Average		70.0 (± 17.9 SD)	

*No. of turtles examined

Parasitemia levels: Considering all infected individuals (12), the intensity of infection for each species matched the species-level prevalence scores; the highest levels of infection were seen in *S. odoratus* and the lowest were in *C. picta* (Table 2). In general, infection intensities appeared to be low in this turtle population, since in most individuals, less than 1% of cells were affected.

Population-level prevalence: The overall prevalence of Haemogregarine parasites in this population was 52.2%. For comparison, we compiled prevalence data from published records of similar investigations throughout North America (Table 3). Prevalence levels from these seven locations (including ours) ranged from 45.2-100.0%. The average of these prevalence values is nearly 70%, so it is not unreasonable to assume that for any given pond in North America, approximately 7 out of every 10 turtles will harbor Haemogregarine blood parasites.

DISCUSSION

Several lines of evidence in this study indicate that prevalence of Haemogregarine blood parasites is highest in turtles most prone to leech parasitism. First, of the turtles we examined, the species most frequently and the most heavily infected with Haemogregarine parasites was the bottom-dwelling *S. odoratus*. Prevalence in this species was twice as high as in *C. picta* and four times as high as in *T. scripta*, which are both aerial baskers (Table 1). Further, the rank order of

these prevalence scores corresponds with that from a prior study where the same species were examined in Kentucky (Strohlein and Christensen, 1984). This pattern makes sense since bottom-dwelling turtles tend to be more frequently infected with leeches than do aerial-basking species (Ryan and Lambert, 2005; McCoy *et al.*, 2007; Readell *et al.*, 2008). Secondly, female turtles, which are more prone to leech parasitism than males because of their larger size (McCoy *et al.*, 2007), had higher incidence of Haemogregarine infection in this study (87.5%) than did males (50.0%). Combined, these results support the idea that Haemogregarine parasitism is highest in turtles that are most affected by leeches.

Haemogregarine blood parasites appear to have little obvious effect on aquatic turtles. All turtles we examined appeared otherwise healthy and the level of Haemogregarine infection we observed was generally low; less than 1% of erythrocytes contained parasites in most turtles. This is consistent with prior investigations (Wang and Hopkins, 1965; McAuliffe, 1977; Strohlein and Christensen, 1984; Siddall and Desser, 1992) and is evidence of their generally benign nature. Furthermore, although the overall prevalence of Haemogregarine parasites in the population we studied in Northeast Georgia (52.2%) was on the low end of the range of values reported for other turtle populations in North America (Table 3), it still indicated that half the turtles in this location were infected. The average of all published reports was 70% and in one population, 100% of the turtles were infected (Acholonu, 1974). Reports from outside North America also point to naturally high prevalence. In one Australian turtle population, prevalence of Haemogregarine infection was 93% (Jakes *et al.*, 2001) and in a Romanian study, 100% of turtles were infected (Mihalca *et al.*, 2002). This naturally high infection rate of Haemogregarine parasites in turtle populations is further evidence of their lack of outward effects on aquatic turtles. Thus, the overall impression gained by these data is that Haemogregarine infections in aquatic turtles are extremely common but also very benign.

Haemogregarine infections can also be long-lasting. In support of this, Sorci (1995) found that lizards heavily infected with Haemogregarine blood parasites remained heavily infected one year later. We also have anecdotal evidence of this lasting infection. We recently obtained a blood sample from a captive *S. odoratus* specimen that was housed singly in an aquarium for over 6 months. It had been captured from a location not far from the pond we sampled in this study. Examination of the blood revealed a Haemogregarine infection (0.14% of cells affected), despite the turtle having no contact with leeches or other turtles for this time period. This could indicate that hosts cannot clear themselves of the infection.

More generally, even if the effects of Haemogregarine infection are minimal in aquatic turtles, the high frequency of infection within populations and the ubiquity of the parasite within North America and abroad makes this host-parasite system especially suited to studies aimed at understanding diseases in aquatic organisms. We suggest that future projects could start by examining the immunological effect (if any) of the parasite on the host, which is an idea that has been raised by others (Mihalca *et al.*, 2002). This idea also has been raised in other host-pathogen systems, where a seemingly-benign intraerythrocytic parasite was found to cause an innate immune response (elevated white blood cell count) by the host (Davis *et al.*, 2009). Another possible direction for research would be to examine the effect of Haemogregarine parasites on erythrocyte development (i.e., numbers of immature cells) within turtles; similar infections in other reptilian hosts can result in increased numbers of immature cells (Oppliger *et al.*, 1996). Both of these ideas emphasize the importance of considering physiological effects of parasites in addition to any measurable outward effects.

ACKNOWLEDGMENTS

We thank Andrew Grosse for help collecting turtles. Michael Yabsley from the University of Georgia Veterinary School kindly performed molecular analyses on blood samples to identify the blood parasite found in this study. We appreciate comments from the Maerz herpetology lab at the University of Georgia, which greatly improved the manuscript. Financial and logistic support provided by the D.B. Warnell School of Forestry and Natural Resources at the University of Georgia.

REFERENCES

- Acholonu, A.D., 1974. *Haemogregarina pseudemydis* n. sp. (Apicomplexa: Haemogregarinidae) and *Pirhemocytion chelonarum* n. sp. in turtles from Louisiana. *J. Protozool.*, 21: 659-664.
- Campbell, T.W. and C.K. Ellis, 2007. *Avian and Exotic Animal Hematology and Cytology*. Blackwell Publishing, Ames, Iowa.
- Davis, A.K., J.L. De Vore, J.R. Milanovich, K. Cecala, J.C. Maerz and M.J. Yabsley, 2009. New findings from an old pathogen: Intraerythrocytic bacteria (Family Anaplasmataceae) in red-backed salamanders *Plethodon cinereus*. *Ecohealth*, 6: 219-228.
- Edney, J.M., 1949. *Haemogregarina stepanowi* Danilewsky (1885) in middle Tennessee turtles. *J. Tennessee Acad. Sci.*, 24: 220-223.
- Hernandez-Divers, S.M., S.J. Hernandez-Divers and J. Wyneken, 2002. Angiographic, anatomic and clinical technique descriptions of a subcarapacial venipuncture site for chelonians. *J. Herpetol. Med. Surgery*, 12: 32-37.
- Jakes, K.A., P. O'Donoghue, M. Munro and R. Adlard, 2001. Hemoprotozoa of freshwater turtles in queensland. *J. Wildlife Dis.*, 37: 12-19.
- Knotkova, Z., S. Mazanek, M. Hovorka, M. Sloboda and Z. Knotek, 2005. Haematology and plasma chemistry of Bornean river turtles suffering from shell necrosis and haemogregarine parasites. *Veterinari Medicina*, 50: 421-426.
- Legler, J.M., 1960. A simple and inexpensive device for trapping aquatic turtles. *Proc. Utah Acad. Sci. Arts Lett.*, 37: 63-66.
- Marquard, W.C., 1966. Haemogregarines and Haemoproteus in some reptiles in Southern Illinois. *J. Parasitol.*, 52: 823-824.
- McAllister, C.T., M.A. Barger and J.N. Stuart, 2008. *Neoechinorhynchus emyditoides* Fisher, 1960 (Acanthocephala : neoechinorhynchidae) from the Mexican plateau slider, *Trachemys gaigeae* (Testudines : emydidae) in New Mexico, USA. *Comp. Parasitol.*, 75: 135-137.
- McAuliffe, J.R., 1977. Hypothesis explaining variations of hemogregarine parasitemia in different aquatic turtle species. *J. Parasitol.*, 63: 580-581.
- McCoy, J.C., E.L. Failey, S.J. Price and M.E. Dorcas, 2007. An assessment of leech parasitism on semi-aquatic turtles in the Western Piedmont of North Carolina. *Southeastern Naturalist*, 6: 191-202.
- Mihalca, A.D., D. Achelaripei and P. Popescu, 2002. Haemoparasites of the genus *Haemogregarina* in a population of European pond turtles (*Emys orbicularis*) from Drăgășani, Vâlcea county, Romania. *Revista Scientia Parasitologica*, 3: 22-27.
- Oppliger, A., M.L. Celerier and J. Clobert, 1996. Physiological and behaviour changes in common lizards parasitized by haemogregarines. *Parasitology*, 113: 433-438.

- Paperna, I., 1989. Developmental cycle of chelonian hemogregarines in leeches with extra-intestinal multiple sporozoite oocysts and a note on the blood stages in the chelonian hosts. *Dis. Aquatic Organisms*, 7: 149-153.
- Readel, A.M., C.A. Phillips and M.J. Wetzel, 2008. Leech parasitism in a turtle assemblage: Effects of host and environmental characteristics. *Copeia*, 1: 227-233.
- Ryan, T.J. and A. Lambert, 2005. Prevalence and colonization of *Placobdella* on two species of freshwater turtles (*Graptemys geographica* and *Sternotherus odoratus*). *J. Herpetol.*, 39: 284-287.
- Segade, P., C. Crespo, C. Ayres, A. Cordero, M.C. Arias, J.M. Garcia-Estevéz and R.I. Blanco, 2006. *Eimeria* species from the European pond turtle, *Emys orbicularis* (Reptilia: Testudines), in Galicia (NW Spain) with description of two new species. *J. Parasitol.*, 92: 69-72.
- Siddall, M.E. and S.S. Desser, 1992. Prevalence and intensity of *Haemogregarina balli* (apicomplexa, adeleina, haemogregarinidae) in 3 turtle species from ontario, with observations on intraerythrocytic development. *Canadian J. Zool.*, 70: 123-128.
- Siddall, M.E. and S.S. Desser, 2001. Transmission of *Haemogregarina balli* from painted turtles to snapping turtles through the leech *Placobdella ornata*. *J. Parasitol.*, 87: 1217-1218.
- Sorci, G., 1995. Repeated measurements of blood parasite levels reveal limited ability for host recovery in the common lizard (*Lacerta vivipara*). *J. Parasitol.*, 81: 825-827.
- Strohlein, D.A. and B.M. Christensen, 1984. *Haemogregarina* sp (Apicomplexa, Sporozoa) in aquatic turtles from Murphys Pond, Kentucky. *Trans. Am. Microscopical Soc.*, 103: 98-101.
- Telford, S.R., 2009. Hemoparasites of the Reptilia: Color Atlas and Text. CRC Press, New York.
- Wang, C.C. and S.H. Hopkins, 1965. *Haemogregarina* and haemoproteus (Protozoa, Sporozoa) in blood of Texas freshwater turtles. *J. Parasitol.*, 51: 682-683.
- Zelmer, D.A. and T.R. Platt, 2008. Structure and similarity of helminth communities of six species of Australian turtles. *J. Parasitol.*, 94: 781-787.